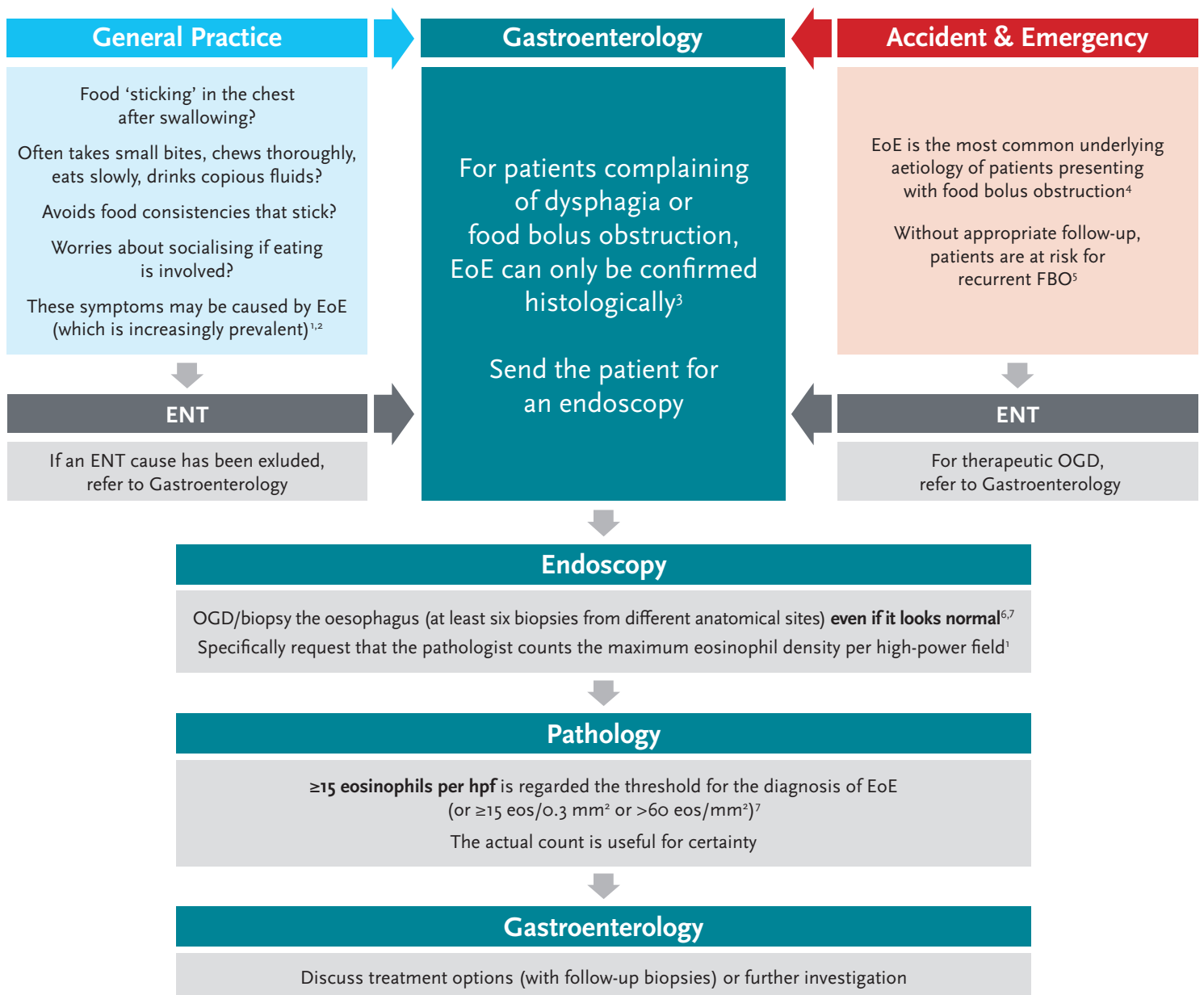


Pathway to EoE diagnosis

Eosinophilic oesophagitis is a rare condition to spot, but it is a rewarding condition to treat



1. Attwood SE. Br J Hosp Med (Lond) 2019; 80(3): 132-8.
2. Arias A *et al.* Aliment Pharmacol Ther 2016; 43(1): 3-15.
3. Lucendo AJ *et al.* United European Gastroenterol J 2017; 5(3): 335-58.
4. Ntuli Y *et al.* Frontline Gastroenterol 2020; 11(1): 11-15.
5. Pfau PR. Tech Gastrointest Endosc 2014; 16(1): 114-19.
6. Attwood S. Clin Med 2013; 13(6): 532-535.
7. Dhar A *et al.* Gut 2022; doi: 10.1136/gutjnl-2022-327326.

ENT: ear, nose & throat
EoE: eosinophilic oesophagitis
eos: eosinophils
FBO: food bolus obstruction
hpf: high-power field
OGD: oesophagogastroduodenoscopy

This pathway was developed by Dr Falk with the input of a panel of physicians expert in the treatment of EoE.

Date of preparation: July 2022
UK-2200118

